

A Paradigm Change in Macro Implant Concept: Inverted Body-Shift Design for Extraction Sockets in the Esthetic Zone

Stephen J. Chu, DMD, MSD, CDT; Jocelyn H.P. Tan-Chu, DDS; Barry P. Levin, DMD; Guido O. Sarnachiaro, DDS; Valentina Lyssova, DDS; and Dennis P. Tarnow, DDS

Abstract: An innovative macro hybrid implant design is aimed at enhancing labial plate dimension and tooth-implant distance while achieving consistent esthetic outcomes. This unique “body-shift” concept in diameter and shape combines a tapered apical portion with a cylindrical coronal portion in a singular implant body design. The overall configuration of the implant is inverted and “convergent” in form toward the implant-abutment interface where bone is thinnest. Conversely, the tapered apical portion is wider where the bone is greatest in volume and vascularity. By reducing the coronal portion of the implant with the inverted body-shift design, a coronal circumferential chamber is created, thereby allowing larger amounts of graft material to be placed labially and interdental to create a net increased bone dimension. Use of the implant is demonstrated in a case report.

The concept of immediate implant placement into fresh extraction sockets with immediate provisional restoration in the esthetic zone has existed for several decades and has become a viable and predictable treatment choice, assuming there is proper understanding and execution on the part of the dental team.¹⁻⁴ Today, the pendulum has swung from the emphasis being on implant survival and osseointegration, though these remain essential, toward treatment outcomes that focus heavily on esthetic results, such as the pink esthetic score.⁵⁻⁷

It has been well-established, understood, and accepted that the thickness of the labial bone plate and soft tissues in the anterior maxilla are extremely thin, ie, ≤ 1 mm, which increases the risk of esthetic dilemmas.⁸⁻¹¹ Consequently, various techniques have been derived to enhance esthetic outcomes at the time of immediate tooth replacement; these include the dual-zone and socket-shield techniques.¹²⁻¹⁸ Studies employing these treatment strategies have shown they can reduce ridge collapse and recession to tenths of millimeters instead of millimeters, thereby affording good esthetic outcomes.^{13,14,16}

Nonetheless, precautions must be taken with regard to immediate implant placement in anterior extraction sites using straight implant

designs, where the probability of apical perforation of the socket is not only real but also extremely high (82%) due to the inherent anatomy of the premaxilla.¹⁹⁻²² Delayed implant placement, cement-retained restorations, angulated screw channel abutments, dynamic or static surgical guides, and subcrestal angle correction (SAC) implants are all proposed solutions to avoid this potential problem.²³

From a biologic perspective, thin avascular labial bone ≤ 1 mm in dimension can survive around natural teeth, because the adjacent periodontal ligament is highly vascular and provides nourishment to this area and to the overlying periosteum.²⁴⁻²⁶ Equally important, bone surrounding an implant after placement must be adequate in dimension; studies support 1.5 mm to 2 mm in width for biologic support that lead to long-term stability.²⁷⁻²⁹ The danger is that if inadequate bone, ie, ≤ 1.5 mm, is present around the implant after placement, the implant may not survive and may succumb to avascular necrosis because endosteum or marrow is absent. Also, changes in craniofacial growth and development can cause esthetic issues around implants long-term.³⁰

Hence, although they are less effective in achieving high primary stability than wider-diameter implants, narrower implants must be considered.³¹⁻³⁴ Increased length is an alternative strategy,



Fig 1.



Fig 2.

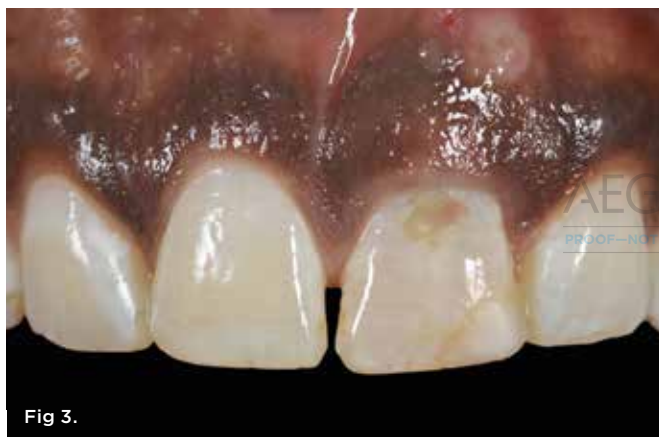

Fig 3.

Fig 1. A “body shift” or inverted body implant design combines a wider tapered apical and narrower cylindrical coronal portion in a singular form. The wider apical portion provides higher primary stability where bone volume is greater and more vascular, and the narrower cylindrical coronal portion creates a bone chamber where a greater amount of graft material can be placed circumferentially around the implant to enhance bone thickness at the crest. **Fig 2.** Occlusal view of the inverted body-shift design depicts how the implant is convergent toward the implant-abutment interface rather than being divergent or wider at the top. The amount of coronal reduction is approximately 0.75 mm to 2 mm depending on the implant diameter. **Fig 3.** Intraoral view of patient with a reconstructed maxillary left central incisor that had fractured. Note fistula tract over the apex of tooth No. 9.

however there is a limit to the amount of apical bone that extends beyond an extraction socket before the floor of the nasal antrum is encroached upon.²¹ Implant diameter has been shown to be highly effective in achieving primary stability in comparison to length, especially in soft bone where undersizing the osteotomy is an essential and useful clinical approach.³¹ However, with wider-diameter tapered implant designs, such as those with a divergent wider coronal portion, the labial gap distance is reduced and the tooth-to-implant distance compromised, especially between the

central-lateral incisor area, which can lead to interdental papilla loss in extraction sockets.²⁸ The horizontal formation of biologic width even with platform-switched designs and/or pressure necrosis of crestal bone can be causative factors.³⁵⁻³⁹ The reality is that the requirements of modern-day implants for biologic and ultimately esthetic needs are no longer the same as those in the 1980s when Brånemark first introduced the concept of osseointegration to North America from Sweden and when survival and integration were the principal directives of treatment.

Recent preclinical and clinical studies, respectively, on an innovative macro hybrid implant design (Inverta™, Southern Implants, southernimplants.com) utilizing a paradigm shift in biologic and esthetic thought has been reported.^{40,41} This unique “body-shift” concept in diameter and shape combines a tapered apical portion with a cylindrical coronal portion in a singular body design (Figure 1). The overall configuration of the implant is inverted and “convergent” in form toward the implant-abutment interface where the bone is thinnest, delicate, and avascular versus divergent (Figure 2). Conversely, the tapered apical portion is wider where the bone is greatest in volume and vascularity. By reducing and shrinking the coronal portion of the implant with the inverted body-shift design, more space is inherently generated, allowing a greater volume of graft material to be placed not only labially but also interdentally into the gap to create a net increased bone dimension. This design also provides a greater tooth-to-implant distance to preserve the interdental attachment of the adjacent natural tooth and, hence, the papillae.

The aforementioned preclinical animal study showed no evidence of apical pressure necrosis with consistent insertion torque values of 100 Ncm on roughly three-quarters of the implants placed.⁴⁰ The results of this histomorphometric study showed that high insertion torque of 100 Ncm will not cause pressure necrosis because the apical portion of the extraction socket possesses not only the greatest amount of bone volume but also is rich in marrow, which has excellent potential for wound healing. The clinical study on 33 implants in the same number of patients showed that a labial bone dimension of 1.6 mm to 2 mm, interdental distance of 2.4 mm to 2.6 mm, and a pink esthetic score of 12.5 was achieved up to 1-year follow-up.⁴¹

Case Report

A 25-year-old African American male patient presented with a fractured maxillary left central incisor with a pre-existing periapical lesion (Figure 3 and Figure 4). A fistula tract was evident over the apex of the tooth (No. 9) as a result of prior endodontic therapy that was failing (Figure 3), and the periapical radiograph of tooth No. 9 showed crestal bone loss, a decemented post/core foundation restoration, and residual apical radiolucency (Figure 4). The patient was given pretreatment antibiotics. The supragingival fibers were severed with sharp dissection using a 15c scalpel, and the clinical crown and residual root segment were removed in toto atraumatically without flap elevation (Figure 5).⁴²

After thorough socket debridement with a surgical spoon excavator it was noted that a slight dentoalveolar dehiscence defect

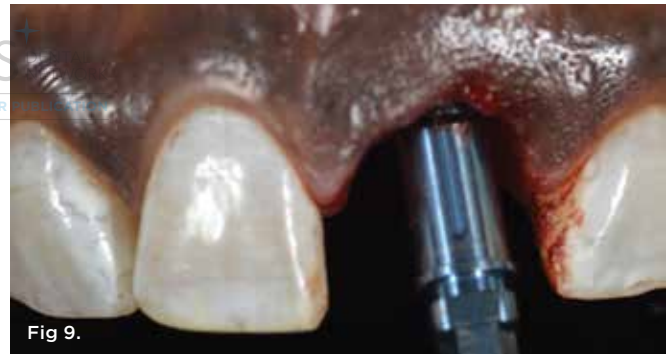
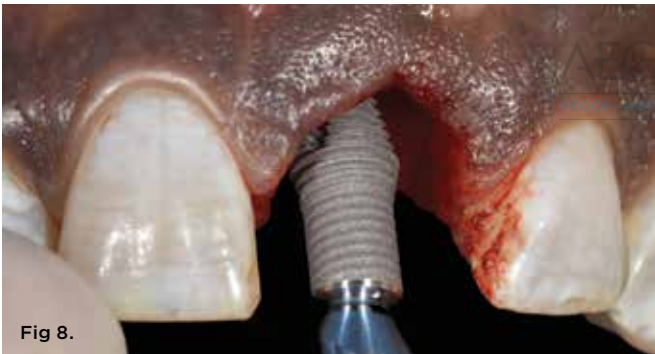
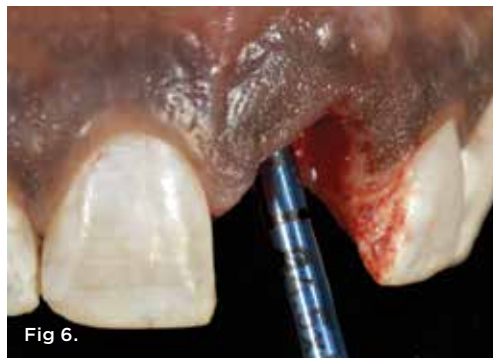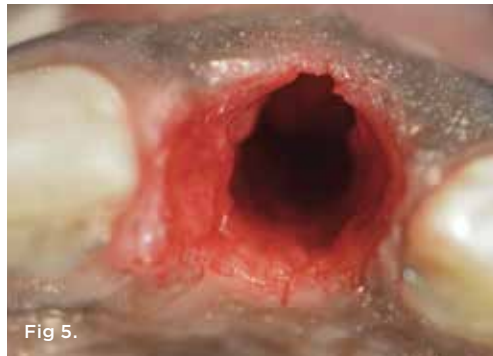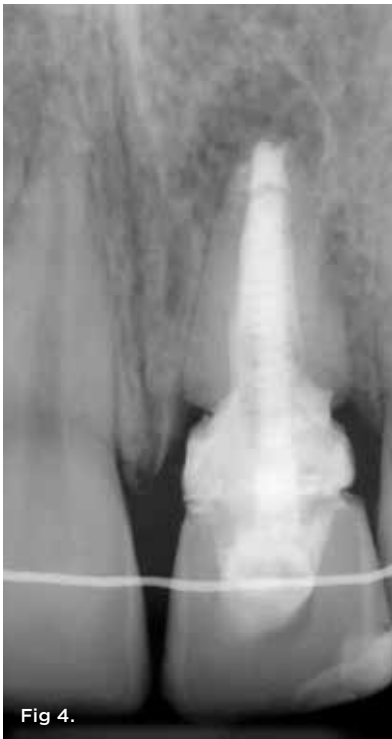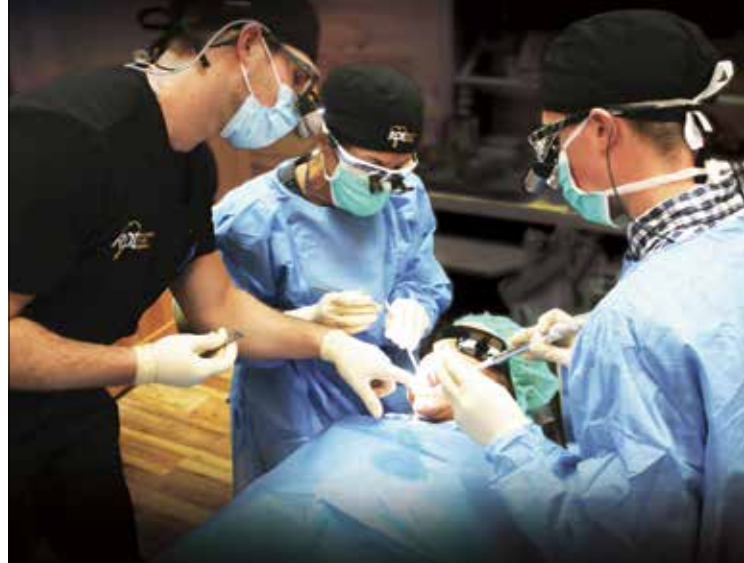Fig 4. Preoperative periapical radiograph of tooth No. 9. **Fig 5.** The supracrestal gingival complex around the tooth was severed with sharp dissection and root removal in a flapless manner. **Fig 6.** The 12-degree co-axis implant feature requires aligning the long axis of the drill shank toward the incisal edge of the adjacent teeth as a point of reference for osteotomy making. Solid extended shank drills were used to eliminate chattering and vibration during this process, leading to precise site preparation. Because only the apical one-half of the implant was being used for primary stability, this procedure must be performed accurately. **Fig 7.** Inverted body-shift design implant with subcrestal angle correction of 12 degrees was premounted to the implant insertion device that counter-matched the angle offset (-12 degrees) to allow the implant to spin true at zero degrees. The prosthetic screw-access hole was on the direct lingual aspect of the implant mount with an orientation groove on the labial side. Two black lines on the implant mount near the implant-abutment interface denote 3 mm of depth from the abutment connection. **Fig 8.** The implant was placed into the osteotomy site with an incisal angulation. The thread depth decreases toward the coronal portion and the thread distance or pitch is 0.6 mm, which means that the implant moves apically only 0.6 mm per full revolution. **Fig 9.** The implant was placed to the second black line from the midfacial free gingival margin designating 3 mm of implant depth and placement to the facial crest of bone. The orientation groove was aligned to the labial aspect with the screw access to the palatal.

of the labial plate was present involving the coronal one-third of the extraction socket. This would be addressed during socket grafting using a cross-linked collagen membrane. The osteotomy was precisely created with the use of extended-length solid shank drills, because only the apical part of the implant was providing primary stability. The incisal edge position was used as a point of reference when drilling the osteotomy and during placement (Figure 6).

Because the bone quality was type III, a decision was made to undersize the osteotomy to 4.5 mm diameter instead of 5 mm. Subsequently, a 13 mm length implant was placed that had an inverted body-shift design with a 5 mm diameter apical portion roughly half the implant length and a 4 mm coronal cylindrical portion about 40% in extent with a subcrestal angle correction feature (Inverta IV-DC4012d-5013) to enable a screw-retained restoration (Figure 7). This implant had a 12-degree angle correction of the

Comprehensive, Hands-on, Dental Implant Placement Education

www.restoratedrivenimplants.com



implant–abutment interface and, therefore, was premounted with a counter-matching holder (Figure 8). The inherent SAC feature redirected the restorative position of the prosthetic screw to the cingulum of the tooth. An alignment groove on the facial aspect of the implant mount helped orient the implant into the proper position (Figure 9).

A screw-retained acrylic provisional restoration attached to a polyetheretherketone (PEEK) temporary cylinder was made with full labial restorative contour to support the peri-implant soft tissues (Figure 10 and Figure 11). A flat non-contoured healing abutment was placed to mitigate graft material from entering the implant–abutment connection, and a cross-linked collagen membrane was placed within the residual socket walls on the facial aspect to cover the bony defect in its entirety to the level of the free gingival margin facially, thereby converting a type 2 socket into a type 1 scenario (Figure 12). The provisional restoration was then replaced after dual-zone socket grafting to contain and protect the graft during the healing phase (Figure 13).¹² The provisional restoration was re-evaluated to make sure it was not in occlusal contact during maximum intercuspal position or lateral excursive movements. This is a critical step in treatment to ensure implant survival with extraction socket implants.

A cone-beam computed tomography (CBCT) scan was taken immediate post-treatment and revealed a labial bone plate thickness of 2.4 mm at the implant–abutment interface (Figure 14). A peri-apical radiograph revealed a tooth-to-implant distance of 3.1 mm at the distal aspect of the central incisor implant between the central and lateral incisors (Figure 15).

The patient continued the antibiotic regiment for 1-week post-treatment and was instructed to not brush the surgical site for 5 to 7 days. At the first postoperative appointment the following week, the wound healing was evaluated and occlusion re-checked. The implant was allowed to heal for 6 months before the first abutment disconnection and final impression making (Figure 16 and Figure 17). After seating an analog implant-level impression coping, flowable composite or pattern resin may be used to register the submergence profile of the peri-implant soft tissues.

A soft-tissue gypsum cast made in the laboratory enabled fabrication of a screw-retained metal-ceramic implant crown. A mesial indirect composite veneer also was created to manage the size and space discrepancy between the two central incisors (Figure 18). The color, texture, and form of the restoration was made to mimic that of the contralateral tooth in one surgical intervention, and the patient was highly accepting of and pleased with the outcome (Figure 19 and Figure 20).

“

The overall configuration of the implant is inverted and “convergent” in form toward the implant–abutment interface where the bone is thinnest, delicate, and avascular versus divergent.

ALCIS+ DEN
PROOF - NOT FOR PUBLICATION

SERIES INCLUDES:

- CT Guided Surgery
- Immediate extraction implant placement
- Suturing techniques and socket preservation
- Principles of graft containment
- Live, clinical implant surgery on multiple patients
- Hands-on prosthetic activities on models
- Pig jaw exercises (extractions, grafting, suturing, etc.)
- Implementation (case acceptance, staff training, etc.)
- Small, student-to-mentor ratio

DES MOINES - FALL 2019

- Series 1 - September 13-14
- Series 2 - September 27-28
- Series 3 - October 25-27

MINNEAPOLIS - SPRING 2020

- Series 1 - Jan. 31 - Feb. 1
- Series 2 - March 6-7
- Series 3 - April 3-5

CHICAGO - FALL 2020

- Series 1 - August 28-29
- Series 2 - September 25-26
- Series 3 - October 23-25

Earn 60 Hours CE Credits

Dental Crafters, Inc. is an ADA CERP Recognized Provider. ADA CERP is a service of the American Dental Association to assist dental professionals in identifying quality providers of continuing dental education. ADA CERP does not approve or endorse individual courses or instructors, nor does it imply acceptance of credit hours by boards of dentistry. Dental Crafters, Inc. designates these seminar activities for 60 hours of continuing education credits.

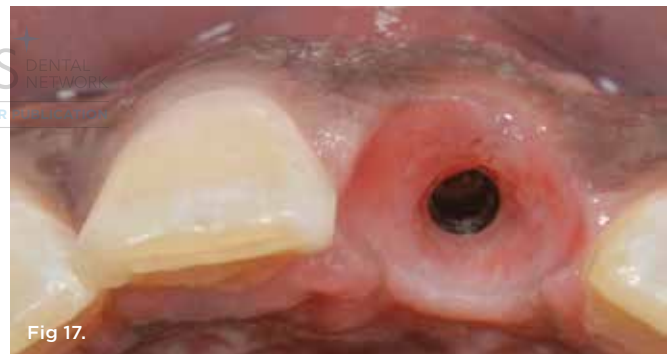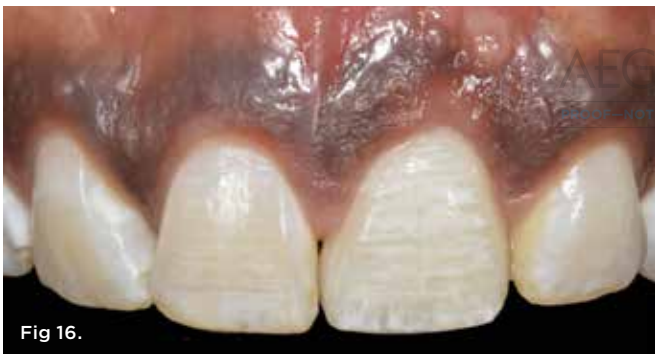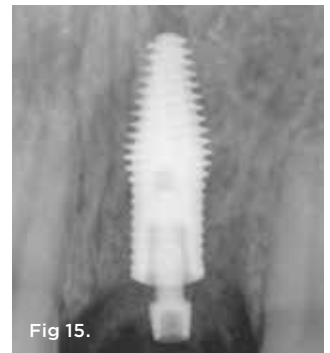


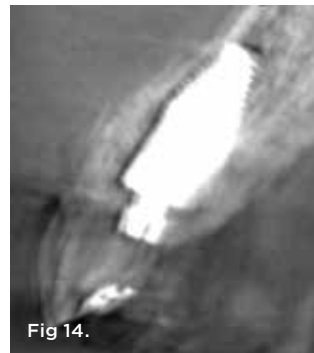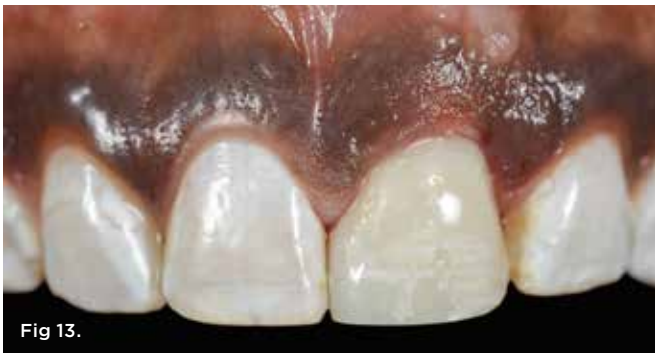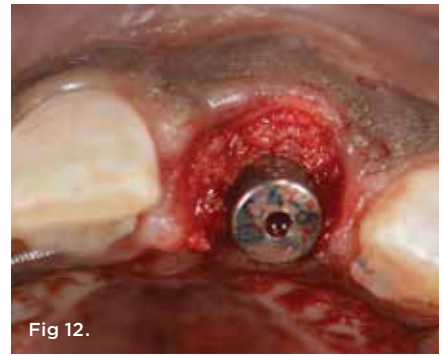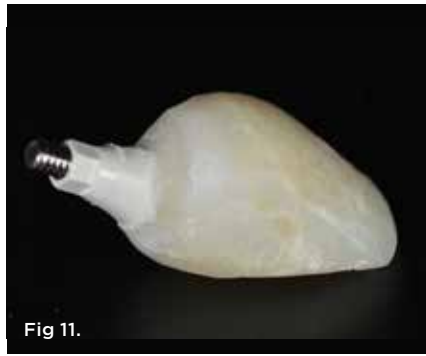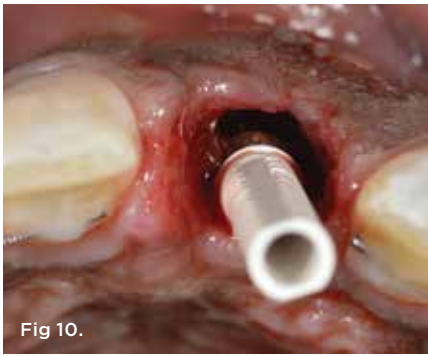Fig 10. A prefabricated PEEK temporary cylinder was connected to the implant-abutment interface. Note that the prosthetic screw access was at the palatal side of the implant due to the subcrestal angle correction design. **Fig 11.** A screw-retained provisional restoration was fabricated from autopolymerizing acrylic resin and characterized accordingly. **Fig 12.** Placement of flat, non-contoured healing abutment. A cross-linked collagen membrane was tucked inside the labial side of the residual socket walls covering the denotalveolar defect, thereby reconstructing a type 2 socket into a type 1. Subsequently, a particle mineralized cancellous allograft was placed between the labial surface of the implant and palatal surface of the membrane into the bone and soft-tissue zones (ie, dual-zone therapy). **Fig 13.** After the healing abutment was removed, the provisional restoration was resealed to contain and protect the graft material during the healing phase of treatment (4 to 5 months). **Fig 14.** Immediate postoperative CBCT showed reconstitution of the labial bone plate due to the bone chamber created by the body shift of the macro hybrid implant design. **Fig 15.** Postoperative periapical radiograph. Note the interproximal bone chamber and greater tooth-to-implant distance for papillae preservation. **Fig 16.** Six months post healing. Note the healthy tissue tone and preservation of the interdental papillae height. **Fig 17.** The buccal-lingual ridge dimension shape was preserved and peri-implant soft tissues enhanced using the dual-zone technique and inverted body-shift design implant.

Conclusion

The use of an inverted body-shift macro hybrid implant design not only can enhance labial plate dimension and tooth-implant distance ≥ 1.5 mm for biologic purposes, but also is conducive to consistent esthetic outcomes in modern-day implant dentistry. This macro change in diameter and shape at the coronal aspect of the implant body at roughly one-half its length may have additional biologic and esthetic implications in not only extraction sockets but also edentulous sites where osteoinduction in situ may occur spontaneously.

DISCLOSURE

Dr. Chu has been a consultant and has a financial interest in products that he has developed for Southern Implants.

ABOUT THE AUTHORS

Stephen J. Chu, DMD, MSD, CDT
Adjunct Clinical Professor, New York University, College of Dentistry, New York, New York; Private Practice, New York, New York

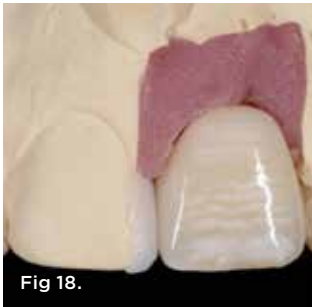

Fig 18.

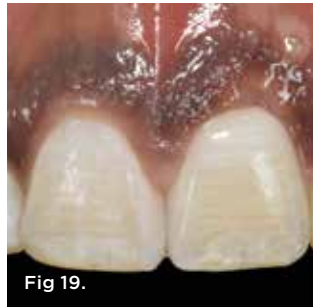

Fig 19.

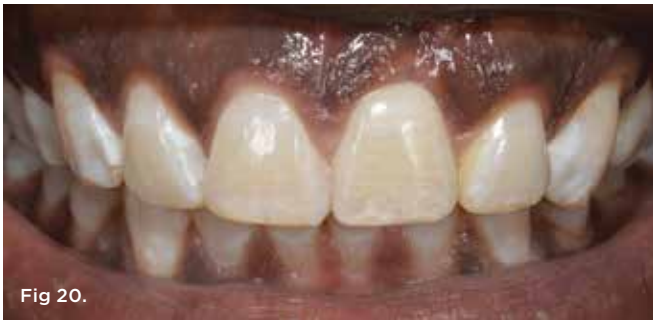

Fig 20.

Fig 18. A no-preparation mesial-facial indirect composite veneer was made to manage the space discrepancy between the two central incisor teeth and close the diastema between them. **Fig 19.** Final implant crown tooth No. 9 and mesial veneer bonded in place. Note the seamless transition in color between the two central incisors. **Fig 20.** Extraoral smile view of patient. Treatment was delivered in one surgical intervention.

Jocelyn H.P. Tan-Chu, DDS
Private Practice, New York, New York

Barry P. Levin, DMD
Clinical Associate Professor, Department of Graduate Periodontology, University of Pennsylvania, Philadelphia, Pennsylvania; Diplomate, American Board of Periodontology; Private Practice, Jenkintown, Pennsylvania

Guido O. Sarnachiaro, DDS
Assistant Clinical Professor, Department of Prosthodontics, New York University, College of Dentistry, New York, New York

Valentina Lyssova, DDS
Private Practice, New York, New York

Dennis P. Tarnow, DDS
Clinical Professor, Department of Periodontology, Director of Implant Education, Columbia University, College of Dental Medicine, New York, New York

REFERENCES

1. Wöhrle PS. Single-tooth replacement in the aesthetic zone with immediate provisionalization: fourteen consecutive case reports. *Pract Periodontics Aesthet Dent.* 1998;10(9):1107-1114.
2. Kan JY, Rungcharassaeng K, Lozada J. Immediate placement and provisionalization of maxillary anterior single implants: 1-year prospective study. *Int J Oral Maxillofac Implants.* 2003;18(1):31-39.
3. Mitrani R, Adolphi D, Tacher S. Adjacent implant-supported restorations in the esthetic zone: understanding the biology. *J Esthet Restor Dent.* 2005;17(4):211-223.
4. Block MS, Mercante DE, Lirette D, et al. Prospective evaluation of immediate and delayed provisional single tooth restorations. *J Oral*

Maxillofac Surg. 2009;67(11 suppl):89-107.

5. Chen ST, Buser D. Clinical and esthetic outcomes of implants placed in postextraction sites. *Int J Oral Maxillofac Implants.* 2009;24 suppl:186-217.
6. Kan JY, Rungcharassaeng K, Lozada JL, Zimmerman G. Facial gingival stability following immediate placement and provisionalization of maxillary anterior single implants: a 2- to 8-year follow up. *Int J Oral Maxillofac Implants.* 2011;26(1):179-187.
7. Cosyn J, Eghbali A, De Bruyn H, et al. Immediate single-tooth implants in the anterior maxilla: 3-year results of a case series on hard and soft tissue response and aesthetics. *J Clin Periodontol.* 2011;38(8):746-753.
8. Araújo MG, Sukekava F, Wennström JL, Lindhe J. Ridge alterations following implant placement in fresh extraction sockets: an experimental study in the dog. *J Clin Periodontol.* 2005;32(6):645-652.
9. Huynh-Ba G, Pjetursson BE, Sanz M, et al. Analysis of the socket bone wall dimensions in the upper maxilla in relation to immediate implant placement. *Clin Oral Implants Res.* 2010;21(1):37-42.
10. Cook DR, Mealey BL, Verrett RG, et al. Relationship between clinical periodontal biotype and labial plate thickness: an in vivo study. *Int J Periodontics Restorative Dent.* 2011;31(4):345-354.
11. Braut V, Borenstein MM, Belsler U, Buser D. Thickness of the anterior maxillary facial bone wall—a retrospective radiographic study using cone beam computed tomography. *Int J Periodontics Restorative Dent.* 2011;31(2):125-131.
12. Chu SJ, Salama MA, Salama H, et al. The dual-zone therapeutic concept of managing immediate implant placement and provisional restoration in anterior extraction sockets. *Compend Contin Educ Dent.* 2012;33(7):524-534.
13. Tarnow DP, Chu SJ, Salama MA, et al. Flapless postextraction socket implant placement in the esthetic zone: part 1. The effect of bone grafting and/or provisional restoration on facial-palatal ridge dimensional change—a retrospective cohort study. *Int J Periodontics Restorative Dent.* 2014;34(3):323-331.
14. Chu SJ, Salama MA, Garber DA, et al. Flapless postextraction socket implant placement: part 2. The effects of bone grafting and provisional restoration on peri-implant soft tissue height and thickness—a retrospective study. *Int J Periodontics Restorative Dent.* 2015;35(6):803-809.
15. Hürzeler MB, Zuhr O, Schupbach P, et al. The socket-shield technique: a proof-of-principle report. *J Clin Periodontol.* 2010;37(9):855-862.
16. Bäumer D, Zuhr O, Rebele S, Hürzeler M. Socket shield technique for immediate implant placement—clinical, radiographic and volumetric data after 5 years. *Clin Oral Implants Res.* 2017;28(11):1450-1458.
17. Gluckman H, Salama M, Du Toit J. A retrospective evaluation of 128 socket-shield cases in the esthetic zone and posterior sites: partial extraction therapy with up to 4 years follow-up. *Clin Implant Dent Relat Res.* 2018;20(2):122-129.
18. Kan JY, Rungcharassaeng K. Proximal socket shield for interimplant papilla preservation in the esthetic zone. *Int J Periodontics Restorative Dent.* 2013;33(1):e24-e31.
19. Sung CE, Cochran DL, Cheng WC, et al. Preoperative assessment of labial bone perforation for virtual immediate implant surgery in the maxillary esthetic zone. A computer simulation study. *J Am Dent Assoc.* 2015;146(11):808-819.
20. Kan JY, Roe P, Rungcharassaeng K, et al. Classification of sagittal root position in relation to the maxillary anterior osseous housing for immediate implant placement: a cone beam computed tomography study. *Int J Oral Maxillofac Implants.* 2011;26(4):873-876.
21. Lau SL, Chow J, Li W, Chow LK. Classification of maxillary central incisors—implications for immediate implant in the esthetic zone. *J Oral Maxillofac Surg.* 2011;69(1):142-153.
22. Gluckman H, Pontes CC, Du Toit J. Radial plane tooth position and bone wall dimensions in the anterior maxilla: a CBCT classification for immediate implant placement. *J Prosthet Dent.* 2018;120(1):50-56.
23. Howes D. Angled implant design to accommodate screw-retained implant-supported prostheses. *Compend Contin Educ Dent.* 2017;38(7):458-463.
24. Spray JR, Black CG, Morris HF, Ochi S. The influence of bone thickness on facial marginal bone response: stage 1 placement through stage 2 uncovering. *Ann Periodontol.* 2000;5(1):119-128.
25. Grunder U, Gracis S, Capelli M. Influence of the 3-D bone-to-implant relationship on esthetics. *Int J Periodontics Restorative Dent.* 2005;25(2):113-119.
26. Pluemsakunthai W, Le B, Kasugai S. Effect of buccal gap distance on alveolar ridge alteration after immediate implant placement: a microcomputed tomographic and morphometric analysis in dogs. *Implant Dent.* 2015;24(1):70-76.
27. Chappuis V, Rahman L, Buser R, et al. Effectiveness of contour augmentation with guided bone regeneration: 10-year results. *J Dent Res.* 2018;97(3):266-274.
28. Esposito M, Ekstubbé A, Gröndahl K. Radiological evaluation of marginal bone loss at tooth surfaces facing single Brånemark implants. *Clin Oral Implants Res.* 1993;4(3):151-157.
29. Cosyn J, Sabzevar MM, De Bruyn H. Predictors of inter-proximal and midfacial recession following single implant treatment in the anterior maxilla: a multivariate analysis. *J Clin Periodontol.* 2012;39(9):895-903.
30. Daftary F, Mahallati R, Bahat O, Sullivan RM. Lifelong craniofacial growth and the implications for osseointegrated implants. *Int J Oral Maxillofac Implants.* 2013;28(1):163-169.
31. Bilhan H, Geckill O, Mumcu E, et al. Influence of surgical technique, implant shape and diameter on the primary stability in cancellous bone. *J Oral Rehabil.* 2010;37(12):900-907.
32. Barikani H, Rashtak S, Akbari S, et al. The effect of implant length and diameter on the primary stability in different bone types. *J Dent (Tehran).* 2013;10(5):449-455.
33. Norton MR. The influence of low insertion torque on primary stability, implant survival, and maintenance of marginal bone levels: a closed-cohort prospective study. *J Oral Maxillofac Implants.* 2017;32(4):849-857.
34. Levin BP. The correlation between immediate implant insertion torque and implant stability quotient. *Int J Periodontics Restorative Dent.* 2016;36(6):833-840.
35. Tarnow DP, Cho SC, Wallace SS. The effect of inter-implant distance on the height of the inter-implant bone crest. *J Periodontol.* 2000;71(4):546-549.
36. Rodríguez-Ciurana X, Vela-Nebot X, Segalà-Torres M, et al. The effect of interimplant distance on the height of the interimplant bone crest when using platform-switched implants. *Int J Periodontics Restorative Dent.* 2009;29(2):141-151.
37. Elian N, Bloom M, Dard M, et al. Effect of interimplant distance (2 and 3 mm) on the height of interimplant bone crest: a histomorphometric evaluation. *J Periodontol.* 2011;82(12):1749-1756.
38. Khayat PG, Arnal HM, Tourbah BI, Sennerby L. Clinical outcome of dental implants placed with high insertions torques (up to 176 Ncm). *Clin Implant Dent Relat Res.* 2013;15(2):227-233.
39. Barone A, Alfonsi F, Derchi G, et al. The effect of insertion torque on the clinical outcome of single implants: a randomized clinical trial. *Clin Implant Dent Relat Res.* 2016;18(3):588-600.
40. Nevins M, Chu SJ, Jang W, Kim DM. Evaluation of an innovative hybrid macrogeometry dental implant in immediate extraction sockets: a histomorphometric pilot study in foxhound dog. *Int J Periodontics Restorative Dent.* 2019;39(1):29-37.
41. Chu SJ, Östman PO, Nicolopoulos C, et al. Prospective multicenter clinical cohort study of a novel macro hybrid implant in maxillary anterior postextraction sockets: 1-year results. *Int J Periodontics Restorative Dent.* 2018;38(suppl):s17-s27.
42. Merheb J, Verbruyssen M, Coucke W, et al. The fate of buccal bone around dental implants. A 12-month postloading follow-up study. *Clin Oral Implants Res.* 2017;28(1):103-108.